



ISSN: 0976-3031

Available Online at <http://www.recentscientific.com>

CODEN: IJRSFP (USA)

International Journal of Recent Scientific Research
Vol. 10, Issue, 01(E), pp. 30540-30543, January, 2019

**International Journal of
Recent Scientific
Research**

DOI: 10.24327/IJRSR

Research Article

RADICULAR CYSTS IN THE ANTERIOR MAXILLA: A CASE REPORT

Sabe-Alarab L^{1*}., Kobyly, M¹., Boutros, EL²., Sabe-Alarab, M³., Saleh, H⁴.,
Jaber, F⁴ and Harba, A⁵

^{1,2}Department of Oral and Maxillofacial Surgery, AlAndalus University, Qadmous, Syria

^{3,4}Department of Oral and Maxillofacial Surgery, Hama University, Hama, Syria

⁵Department of Oral and Maxillofacial Surgery, Damascus University, Damascus, Syria

DOI: <http://dx.doi.org/10.24327/ijrsr.2019.1001.3078>

ARTICLE INFO

Article History:

Received 4th October, 2018

Received in revised form 25th
November, 2018

Accepted 23rd December, 2018

Published online 28th January, 2019

Key Words:

Radicular Cyst, Inflammatory Cyst,
Enucleation and Periapical Cyst.

ABSTRACT

Radicular cysts are the most common of all jaw bone cysts. As a result of inflammation radicular cysts arise from the epithelial residues in the periodontal ligament. Generally, they are a result of pulpal infection following dental caries. Radicular cysts treatment involves surgical approach, more or less aggressive.

In this case we presented a 35-year-old male patient with large radicular cyst in the anterior maxilla. However, the cyst was completely removed by enucleation without intraoperative and postoperative complications.

The presented case supports the opinion that careful enucleation of large cysts without complications, such as damages of surrounding anatomical structures.

Copyright © Sabe-Alarab L et al, 2019, this is an open-access article distributed under the terms of the Creative Commons Attribution License, which permits unrestricted use, distribution and reproduction in any medium, provided the original work is properly cited.

INTRODUCTION

Cyst is defined as a pathologic epithelium lined cavity usually containing fluid or semi-solid material. Odontogenic cysts are derived from the epithelium associated with the development of dental apparatus (Shafer 2009). According to the World Health Organization, cysts in the jawbone can be classified as developmental, neoplastic, and inflammatory origin (Kramer IR et al, 1992; Main DM 1985). Radicular cyst is an inflammatory origin and it is believed to be formed by inflammatory proliferation of epithelial cell rests of Malassez in the area of apical periodontitis of a tooth having an infected necrotic pulp (Lin LM 2009). Radicular cysts are the most common inflammatory jaw cysts and develop as a sequel of untreated dental caries with pulp necrosis and periapical infection (Jones A et al, 2006).

Epidemiology

Radicular cysts are the most common type of all jawbone cysts and comprise about 52-68% of all the cysts affecting the jawbone (Shear M 1992; Killey HC et al, 1977).

The anterior region of the maxilla and premolar region of the mandible are more frequently involved than other parts of the jaw bone by radicular cysts (Borg G et al, 1974).

Clinical and radiographic presentation

Radicular cysts usually present as an osteolytic lesion at the periapical area of a tooth with an infected necrotic pulp on conventional radiography and cone beam computed tomography. If an osteolytic periapical lesion is more than 2 cm² in diameter, It is believed to be a cystic lesion (Lalonde ER 1970; Natkin E et al, 1984). In addition, if a well-demarcated periapical osteolytic lesion is bordered by a thin rim of cortical bone, there is a strong probability that the lesion is a cyst (Weber AL 1993; Scholl RJ et al, 1999).

Site of Presentation

These cysts can occur in the periapical area of any teeth and at any age but they are seldom seen associated with the primary dentition. Anatomically, the apical cysts occur in all tooth-bearing sites of the jaw bones but they are more frequent observed in maxillary than mandibular teeth. In the maxilla, the anterior region appears to be more prone to cyst development whereas in the mandible the radicular cysts occur more frequently in the premolar region (Shear M, 1992).

*Corresponding author: **Kalirajan R**

Department of Oral and Maxillofacial Surgery, AlAndalus University, Qadmous, Syria

Treatment

It involves more or less aggressive surgical approach. Although enucleation of jaw cysts, the so-called “cystectomy”, and primary closure of the defect still represents the “state of the art procedure” (Ettla T *et al*, 2012), enabling spontaneous bone healing (Chiapasco M *et al*, 2000; Ihan Hren N and Miljavec M. 2008).

More conservative approach, comprising just decompression of the cystic cavity as the primary procedure, has recently become popular, especially in case of large jaw bone cysts (> 3cm²) (Swantek JJ *et al*, 2012; Enislidis G *et al*, 2004).

The aim of this report was to present an adult patient with a large radicular cyst in the anterior maxilla, which is completely removed by enucleation without intraoperative and postoperative complications.

CASE REPORT

A male Patient aged 35years reported to the department of Oral Surgery with a chief complaint of pain, swelling and pus discharge in upper right front region of mouth for two months. On panoramic examination, there was large periapical radiolucency in relation to 11, 12 (Figure 1).

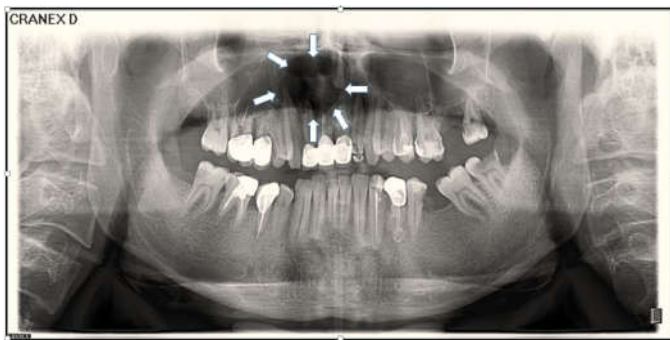

Figure 1 Panoramic radiograph. Arrows refer to the border of the cyst

On probing and radiograph examination there was extensive bone loss in relation to the same teeth.

There was a soft fluctuant swelling labial to the above mentioned teeth with pus discharge. Swelling was approximately 3 cm in diameter.

Due to the existing infection at the time of examination, we made intraoral incision for drainage and commenced with antibiotic (ceftriaxon 1g I.M. once daily) and orally (metronidazole 0.5g Tab 3 times daily) for a week.

Root canal was opened and old filling was removed. After determination of working length and biomechanical preparation, calcium hydroxide medicament was placed intracanal for 1 week.

Based on the radiographic finding, the patient was advised for surgical treatment (enucleation) of the lesion under local anesthesia. Although radiography pointed out a possible risk of injuring the nasopalatine bundle, nasal floor, maxillary sinus, we decided to enucleate the cyst surgically. Patient was prepared for surgery in the next visit which included surgical enucleation of the cyst and filling of involved teeth. The patient was informed about the risks and adopted the surgical plan.

First, we retreated the mentioned teeth and filled canals with gutta percha at the time of surgery (Figure 2).

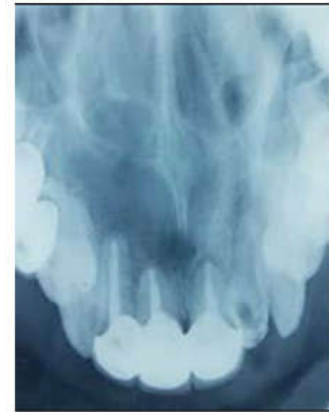

Figure 2 Occlusal radiograph after filling canals. Arrows refer to the border of the cyst

After administration of local anesthesia (infraorbital nerve block, nasopalatine nerve block and local infiltration using 2% lidocaine hydrochloride with adrenaline 1:80000 solution), crevicular incision was made in the labial region extending from the left premolar until the right first premolar with vertical releasing incision.

A full thickness mucoperiosteal flap was reflected. After uplifting the mucoperiosteal flap, a cortical perforation of the buccal cortex of the maxilla could be seen, as well as the membrane of the radicular cyst (Figure 3).

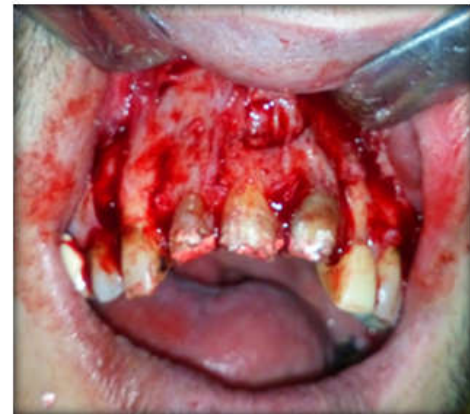

Figure 3 Mucoperiosteal Flap

After careful separation of the cystic membrane from surrounding anatomical structures and the nasopalatine bundle, the cyst was completely enucleated and the defect rinsed with saline (Figure 4,5 and 6).

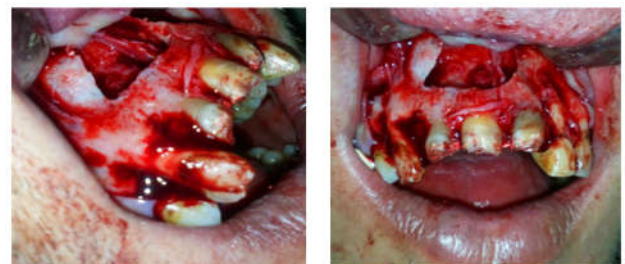


Figure 4 The cyst was completely enucleated

The wound was primarily closed with 4-0 silk sutures (Figure 5).

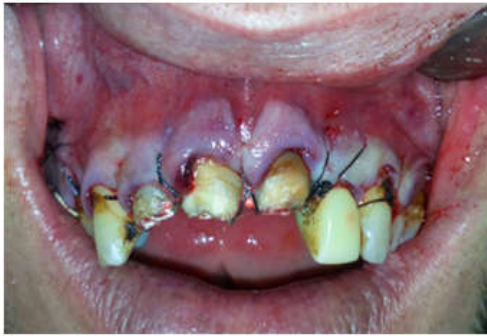

Figure 5 The suture

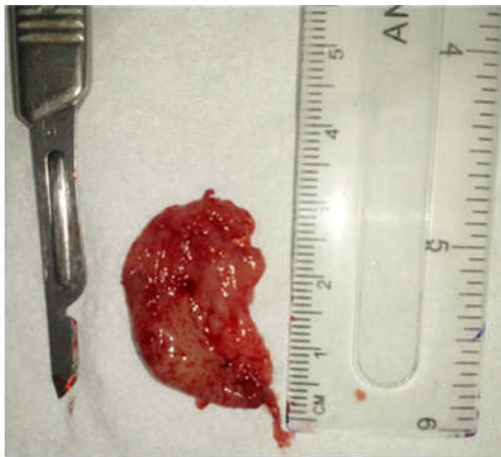

Figure 6 The whole cyst

Histopathologically revealed presence of varying thickness of epithelium with fibro cellular connective stroma. At higher magnification, the epithelium was disrupted with infiltration of chronic inflammatory cells along with vacuolations within the epithelium. Connective tissue showed dense infiltration of lymphocytes and plasma cells with few macrophages (Figure 7). A diagnosis of radicular cyst was given.

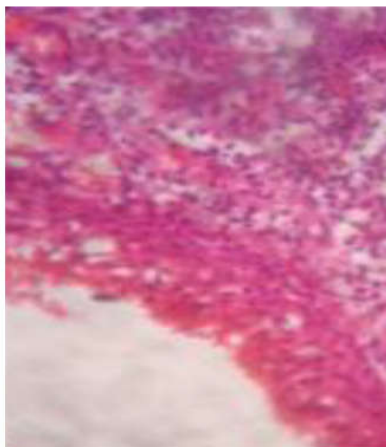


Figure 7 H and E stained section under 10x magnification

Postoperatively, the patient received antibiotics orally (amoxicillin 500 mg cap four times daily), (metronidazole 0.5g Tab three times daily) and (paracetamol 500 mg Tab four times daily) for seven days, when sutures were removed. postoperative complications were not noticed. normal sensation

in the innervation area of the nasopalatine nerve and the follow up was: 1 day, 2 days, 3 days, 1 week, 1 month and 3 months after surgery.

DISCUSSION

The incidence of radicular cysts is about 0.5-3.3% of the total number in both primary and permanent dentition (Shear M 1983). These cysts occur more commonly between third and fifth decades, more common in males than in females, and more frequently found in the anterior maxilla than other parts of oral cavity (Joshi. N *et al*, 2011).

Radicular cysts are usually asymptomatic and are left unnoticed, until detected by routine radiographic examination where as some long standing cases may undergo an acute exacerbation of the cystic lesion and develops signs and symptoms such as swelling, tooth mobility and displacement of unerupted tooth (Mass E *et al*, 1995).

Affected teeth are always non-vital and may show discoloration or treated badly (Lustmann J and Shear M, 1985). As the cyst increases in size, bony covering becomes very thin and cortical perforation may occurred as in present case (Shear M, 1992).

Radiographically most radicular cysts appear as round or pear shaped unilocular radiolucent lesions in the periapical region. The cysts may displace adjacent teeth or cause mild root resorption. Radiographically, distinguishing between a granuloma and a cyst is impossible, although some say that if the lesion larger than 2 cm is more likely to be a cyst (Cawson RA *et al*, 2002; Ragezi JA *et al*, 2003).

That can be characteristically appreciated in the present case. Treatment options for radicular cysts can be conventional nonsurgical when lesion is localized or surgical treatment like enucleation, marsupialization or decompression when the lesion is large (Ribeiro Paulo Domingos *et al*, 2004).

This case report presents successful surgical enucleation of large radicular cyst alongside with root canal treatment.

Histological Features: Almost all radicular cysts are lined wholly or partly by nonkeratinized stratified squamous epithelium. This lining may be discontinuous ranging in thickness from 1-50 cell layers. In the early stages epithelium lining may be proliferative and show arcading with intense inflammatory infiltrate. As the cyst enlarges, the lining becomes quiescent and fairly regular with a certain degree of differentiation to resemble simple stratified squamous epithelium.

Keratin formation (2% of cases) when present, affects only part of the cyst wall. Inflammatory cell infiltrate in the proliferating epithelium consists predominantly of PMN's and the adjacent fibrous capsule is infiltrated by chronic inflammatory cells (Shear M and Speight P, 2007).

CONCLUSION

The presented case supports the opinion that careful enucleation of large maxilla cysts could be done without complications, such as damages of surrounding anatomical structures.

References

- Borg G, Persson G, Thilander H. (1974) A study of odontogenic cysts with special reference to comparisons between keratinizing and non-keratinizing cysts. *Sven Tandlak Tidskr.*; 67: 311-325.
- Cawson RA, Odell EW, Porter S. *Cawsons essentials of oral pathology and oral medicine*. 7th edition, Churchill Livingstone, Edinburgh ; 15: 139-150 (2002).
- Chiapasco M, Rossi A, Motta JJ, Crescentini M. (2000) Spontaneous bone regeneration after enucleation of large mandibular cysts: a radiographic computed analysis of 27 consecutive cases. *J Oral Maxillofac Surg*; 58(9): 942-8.
- Enislidis G, Fock N, Sulzbacher I, Ewers R. (2004) Conservative treatment of large cystic lesions of the mandible: a prospective study of the effect of decompression. *Br J Oral Maxillofac Surg*; 42(6): 546-50.
- Ettla T, Gosau M, Saderb R, Reicherta ET. (2012) Jaw cysts - Filling or no filling after enucleation?, A review. *J Cranio Maxillofac Surg* ; 40(6): 485-93.
- Ihan Hren N, Miljavec M. (2008) Spontaneous bone healing of the large bone defects in the mandible. *Int J Oral Maxillofac Surg*; 37(12): 1111-6.
- Jones A, Craig G, Franklin C. (2006) Range and demographics of odontogenic cysts diagnosed in a UK population over a 30-year period. *Journal of Oral Pathology & Medicine*. ;35(8):500-7.
- Joshi. N, Sujana S, Rachappa M. (2011) An unusual case report of bilateral mandibular radicular cysts. *Contemporary Clinical Dentistry*; 2(1):59-62.
- Killey HC, Kay LW, Seward GR. 3rd edn. Edinburgh and London Churchill Livingstone (1977).
- Kramer IR, Pindborg JJ, Shear M. The WHO Histological Typing of Odontogenic Tumors: a commentary on the second edition. *Cancer*.; 72: 2988-2994. (1992)
- Lalonde ER. (1970) A new rationale for the management of periapical granulomas and cysts: an evaluation of histopathological and radiographic findings. *J Am Dent Assoc*.; 80: 1056-1059.
- Lin LM, Ricucci D, Lin J, (2009) Rosenberg PA. Non-surgical root canal therapy of large cyst-like inflammatory periapical lesions and inflammatory apical cysts. *J Endod*.; 35: 607-6 15.
- Lustmann J, Shear M. (1985) Radicular cysts arising from deciduous teeth: Review of the literature and report of 23 cases. *International Journal of Oral Surgery*; 14(2):153-61.
- Main DM. Epithelial jaw cysts: 10 years of the WHO classification. *J Oral Pathol.*; 14: 1-7. (1985)
- Mass E, Kaplan I, Hirshberg A. (1995) A clinical and histopathological study of radicular cysts associated with primary molars. *J Oral Pathol Med*; 24:458-61.
- Natkin E, Oswald RJ, Carnes LI. (1984) the relationship of lesion size to diagnosis, incidence, and treatment of periapical cysts and granulomas. *Oral Surg Oral Med Oral Pathol.*; 57: 82-94.
- Ragezi JA, Scubba JJ, Jordan Rck. *Oral pathology: clinicalpathologic correlations*. 4th edition, WB Saunders, St Louis.: 241-54. (2003)
- Ribeiro Paulo Domingos, Gonçalves Eduardo S, Neto Eduardo S. (2004) Surgical approaches of extensive periapical cyst. Considerations about surgical technique. *Salusvita Bauru*; 23:317-328.
- Scholl RJ, Kellett HM, Neumann DP, (1999) Lurie AG. Cysts and cystic lesions of the mandible: clinical and radiologic-histopathologic review. *Radiographics*.; 19: 1107-1124.
- Shafer's textbook of oral pathology, 6th ed, 487-490. (2009).
- Shear M, Speight P. *Cysts of oral and maxillofacial region*, 4th ed. Oxford: Blackwell Mungsgaard, (2007).
- Shear M. *Cysts of the oral region*, 3rd edition. Boston wright.: 136-70. (1992)
- Shear M. *Cysts of the Oral Regions*. 2nd ed. Bristol: John Wright and Sons, (1983).
- Shear M. *Cysts of the oral regions*. 3rd ed. Boston: Wright, 136-70. (1992)
- Shear M. *Cysts of the oral regions*. 3rd edn. Oxford, Wright. (1992).
- Swantek JJ, Reyes MI, Grannum RI, Ogle OE. (2012) A technique for long term decompression of large mandibular cysts. *J Oral Maxillofac Surg*; 70(4): 856-9.
- Weber AL. (1993) Imaging of cysts and odontogenic tumors of the jaw. Definition and classification. *Radiol Clin North Am.*; 31: 101-120.

How to cite this article:

Sabe-Alarab L *et al.* 2019, Radicular Cysts In The Anterior Maxilla: A Case Report. *Int J Recent Sci Res*. 10(01), pp. 30540-30543. DOI: <http://dx.doi.org/10.24327/ijrsr.2019.1001.3078>
